

## Case Report

### Pulmonary Tuberculosis with ARDS and Hemophagocytic Syndrome – A case report

Prabhas Prasun Giri\*, Priyankar Pal\*\*, Nupur Ganguly\*\*, Apurba Ghosh\*\*\*

\*RMO Cum Clinical Tutor, Institute of Child Health, \*\*Associate professor, Institute of Child Health, \*\*\*Professor of Pediatrics, Institute of Child Health, Kolkotta

Received:6-Aug-2014/Accepted:12-Oct-2014/Published online:15-Nov-2014

#### ABSTRACT:

Hemophagocytic lymphohistiocytosis(HLH) is a heterogeneous group of clinical syndromes, either familial or genetic in origin or secondary, characterised by uncontrolled non-malignant proliferation of T-lymphocytes, histiocytes and macrophages leading to a cytokine storm and manifest as prolonged fever, organomegaly, cytopenia, hyperferritinemia and demonstrable hemophagocytosis in the bone marrow. Secondary infection associated HLH(IAHLH) can be triggered by many infections, mostly viral. Here we present a case of Pulmonary tuberculosis complicated by ARDS and HLH.

#### Introduction

Tuberculosis continues to be an important cause of morbidity and mortality for children worldwide.<sup>1</sup> Very rarely it can manifest as diffuse bilateral X-ray changes suggestive of Acute Respiratory Distress Syndrome (ARDS)<sup>2</sup>. ARDS is an emergency and mostly need mechanical ventilation ,non-invasive or invasive. ARDS can be a pulmonary manifestation of HLH.<sup>3</sup> But tuberculosis complicated by both ARDS and HLH is extremely rare and till date there is no case report. Our case, 11 year old boy, presented with PUO, developed ARDS and HLH and ultimately diagnosed to be having tuberculosis.

#### Case Report

10yr old boy admitted with history of fever for 14 days. Clinical examination revealed only a just palpable liver. Investigation showed Hb 11.2gm%, TLC 6400/cmm, DLC - N 54 L38 M02 E03 B 02, Malaria Parasite not found, SGPT 220 IU/dl, Widal 1:320, chest x-ray noncontributory. Assuming a clinical diagnosis of enteric fever, iv ceftriaxone was started. Over next few days his fever decreased in

intensity but did not subside. Mantoux test and blood culture were negative.

On day 5 of admission, he suddenly developed severe respiratory distress. Respiratory rate was 86/min, SPO2 in room air was 56%, with 12 litres of O2 it was only 88-90%. There was no accessory sounds in the chest, B/L VBS was there and air entry was good. Chest x ray showed B/L diffuse patchy opacities suggestive of ARDS. (figure 1) ABG revealed severe hypoxemia and so he was intubated and ventilated. Investigations showed a raised CRP with pancytopenia (TLC-3200, PLATELET 80,000, HB 8.2). HRCT showed features of ARDS with cavity and nodules in left upper lobe. (figure 2)

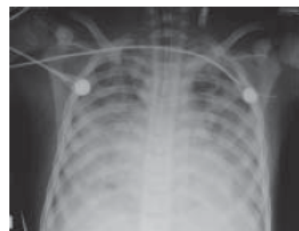

Fig 1

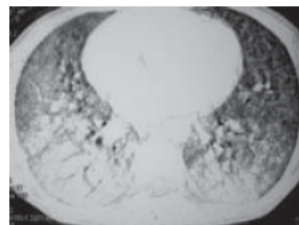


Fig.2

#### Correspondence:

Dr Prabhas Prasun Giri  
Flat C1; ANANDAN; 173, Sarat Ghosh Garden Road  
Kolkata-31, Wesbengal, India  
Mobile- +91-90519-58420  
Email- dr.prabhas@yahoo.co.in

Because of the sudden deterioration with development of cytopenia, HLH was thought of and corresponding tests showed Ferritin 7568ng/dl, TG 423mg/dl, LDH 2543IU/dl, Fibrinogen 123gm/L, FDP 7800. IV Immunoglobulin (2gram/kg) with IV dexamethasone 10mg/m<sup>2</sup> /day was started following bone marrow aspiration.

Bronchoalveolar lavage showed acid fast bacilli and it was positive for Mycobacterium Tuberculosis Complex by DNA amplification (TB PCR Qualitative). Bone marrow revealed plenty of hemophagocytes.

Following initiation of therapy, blood parameters improved in the next 72 hours and he was extubated on day 5 of Mechanical ventilation and discharged on day 26 of admission with 4 antitubercular drugs (HRZE) and steroid. Dexamethasone was given for 8 weeks in tapering doses as per HLH 2004 protocol, but no other chemotherapeutic drugs like Cyclosporine or Etoposide was used.

He is on regular follow up for last 2 years and remains asymptomatic.

### Discussion

Children contribute a significant proportion of the disease burden of tuberculosis and suffer severe disease-related morbidity and mortality, particularly in endemic areas<sup>1</sup>. Pulmonary tuberculosis can manifest in various way in pediatric population. Symptomatic primary complex, progressive primary disease, endobronchial tuberculosis, tubercular pleural effusion and miliary tuberculosis are the commonest modes of presentation whereas gross fibrosis or cavitating lung lesions are uncommon<sup>4</sup>.

ARDS (Acute respiratory distress syndrome) can result from either a direct lung injury or from a downstream inflammatory process manifested by profound hypoxemia and respiratory failure. ARDS has been traditionally described as: the acute onset of respiratory failure with bilateral infiltrates on chest radiograph associated with hypoxemia as defined by a PaO<sub>2</sub>/FiO<sub>2</sub> ratio  $\leq$ 200 mmHg, and there should be no evidence of left atrial hypertension or a pulmonary capillary pressure should be  $<$ 18 mmHg (if measured) to rule out cardiogenic edema. In pediatric age group, ARDS is largely secondary to lung infections<sup>5</sup>.

ARDS as a manifestation of pulmonary tuberculosis in children is extremely rare.

Hemophagocytic lymphohistiocytosis (HLH) occurs due to uncontrolled proliferation and activation of macrophages, cytotoxic t cells and antigen presenting cells resulting in a state of hypercytokinemia<sup>6</sup>. Any infection can trigger HLH, though most are triggered by viral infections.<sup>7</sup>

Pulmonary tuberculosis manifesting as ARDS has rarely been reported in adults. Miliary tuberculosis is an uncommon but important treatable cause of ARDS. Mohan et al<sup>8</sup> reported 6 cases of miliary TB who developed ARDS in the course of their disease. Agarwal et al<sup>2</sup> also demonstrated that nine (4.9%) out of 187 adult patients had ARDS secondary to tuberculosis. But tubercular ARDS in pediatric population is extremely rare and limited to few case reports only.

Tuberculosis is considered a rare cause for infection associated secondary HLH. Wen su et al<sup>9</sup> reported a case of tuberculosis induced HLH in a 58 year old patient under hemodialysis. Gupta et al<sup>10</sup> presented a case of generalised lymphadenopathy, hepatosplenomegaly and progressive cytopenias in a 17-year-old male who was simultaneously diagnosed to have HLH and Tuberculosis as AFB was demonstrated from the lymph node aspirates. Deshpande et al<sup>11</sup> also reported a case of miliary tuberculosis with hemophagocytosis in a 2 months old infant.

The most common pulmonary manifestation of HLH is Acute lung injury or ARDS. Lahm et al<sup>12</sup> reported a case of Adenovirus associated HLH with ARDS. Roxana Mansour Ghanaiee et al<sup>13</sup> also reported few cases of HLH in pediatric population in Iran who developed ARDS.

But, Pulmonary tuberculosis with ARDS with secondary HLH is yet to be reported in literature. IAHLH does not always need full HLH 2004 therapy protocol; they can often be treated successfully with low intensive therapy depending upon the severity, and the initial response to steroids. Many of them can be treated with steroid only protocol<sup>14</sup> as this child received only steroid in a tapering dosage over 8 weeks.

**Conflict of Interest:** None **Source of Funding:** None

### Reference

1. Banu Rekha, Soumya Swaminathan. Childhood tuberculosis

- global epidemiology and the impact of HIV. Paediatric Respiratory Reviews. Volume 8, Issue 2, June 2007, Pages 99–106
- Ritesh Agarwal, Dheeraj Gupta, Ashutosh N. Aggarwal, Digamber Behera, Surinder K. Jindal. Experience with ARDS caused by tuberculosis in a respiratory intensive care unit. *Intensive Care Medicine*. September 2005, Volume 31, Issue 9, pp 1284-1287
  - Fitzgerald NE, MacClain KL. Imaging characteristics of Hemophagocytic lymphohistiocytosis. *Pediatr Radiol*. 2003; 33(6): 392-401.
  - Seth V, Kabra SK. *essentials of tuberculosis in children*, 3<sup>rd</sup> ed. New Delhi; Jaypee Publishers, 2006.
  - Bernard GR1, Artigas A, Brigham KL, Carlet J, Falke K, Hudson L, Lamy M, Legall JR, Morris A, Spragg R. The American-European Consensus Conference on ARDS. Definitions, mechanisms, relevant outcomes, and clinical trial coordination. *Am J Respir Crit Care Med*. 1994 Mar; 149(3 Pt 1): 818-24.
  - Janka GE. Familial and acquired hemophagocytic lymphohistiocytosis. *Annu Rev Med*. 2012; 63:233-246.
  - Hideaki Kikuta, Yukio Sakiyama, Shuzo Matsumoto, Tsutomu Oh-Ishi, Takashi Nakano, Tetsuro Nagashima, Toshiaki Oka, Takashi Hironaka, and Kanji Hirai. Fatal Epstein-Barr Virus-Associated Hemophagocytic Syndrome. *Blood*, Vol82, No 11 (December 1), 1993: pp 3259-3264
  - A Mohan, S K Sharma, J N Pande. Acute respiratory distress syndrome (ARDS) in miliary tuberculosis: a twelve year experience. *The Indian journal of chest diseases & allied sciences* 01/1996; 38(3):157-62.
  - Nai-Wen Su, Chi-Kuan Chen, Gon-Shen Chen, Ruey-Kuen Hsieh, Ming-Chih Chang. A case of tuberculosis-induced hemophagocytic lymphohistiocytosis in a patient under hemodialysis. *International Journal of Hematology*, 2009, Volume 89, Number 3, Page 298
  - Gupta AP, Parate S N, Bobhate S K, Anupriya. Hemophagocytic syndrome: A cause for fatal outcome in tuberculosis. *Indian J Pathol Microbiol* 2009; 52:260-2
  - A. Deshpande, Priyanka S. Nayar, Avinash M. Pradhan, and Rumma V. Manchanda. Miliary Tuberculosis with Hemophagocytosis in a Two Months Old Infant. *Indian J Hematol Blood Transfus*. Sep 2010; 26(3): 115–117.
  - Tim Lahma, Helena N. Spartzb, Dean A. Hawleyb, et al. Fatal adenovirus serotype 21 infection associated with hemophagocytic lymphohistiocytosis and multiorgan failure. *Respiratory Medicine CME*. Volume 3, Issue 4, 2010, Pages 223–225
  - Roxana Ghanaie, Reza Shiari, Abdollah Karimi, Shahnaz Armin, Alireza Fahimzad, Faride Shiva, and Mohammad Arzanian. A case series report of Iranian children Hemophagocytic Lymphohistiocytosis syndrome. *Arch Pediatr Infect Dis*. 2012; 1(1):31-35
  - Prabhas Prasun Giri, Priyankar Pal, Apurba Ghosh, Rajiv Sinha. Infection-associated haemophagocytic lymphohistiocytosis: a case series using steroids only protocol for management. *Rheumatol Int* 2013 May 23;33(5):1363-6